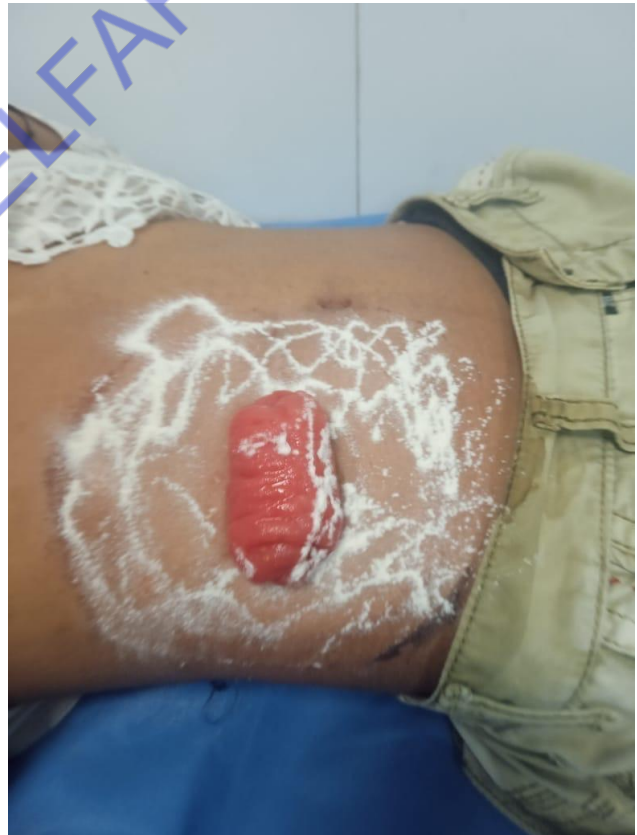
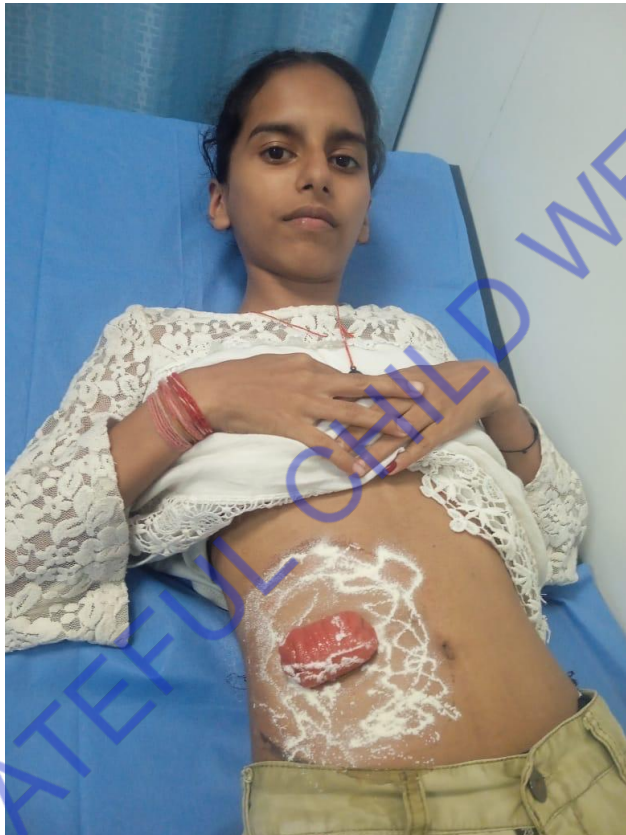
## DIVYANSHI – STOMA



Divyanshi, a 12-year-old girl, is bravely fighting a serious medical condition that requires her to live with a stoma—a surgical opening in the abdomen that allows waste to leave the body. This condition not only affects her physically but also emotionally, as she faces daily discomfort and challenges that no child should endure. Divyanshi comes from a financially poor family, and her mother is the only caregiver struggling to provide for her treatment and basic needs. They are in urgent need of support to manage ongoing medical care, stoma supplies, and potential future surgeries. We humbly request your kind donations to help Divyanshi live a healthier and more comfortable life. Every contribution, no matter how small, will make a big difference.





**Grateful Child  
Welfare Foundation**

Rz -24 Madanpuri West Sagarpur  
New Delhi-110046  
+91-9958114443 // we@gcwfnngo.org

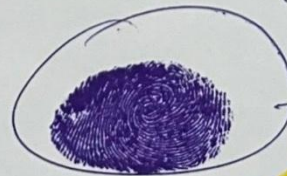श्रीवा में,  
श्रीमान,  
Grateful Child Welfare Foundation  
New Delhi -46

:विषय: बेटी की सहायता हेतु आर्थिक सहायत के लिए निवेदन पत्र

महोदय: मेरी नाम मीता पाठक हैं ग्राम बलरामपुर कैलाबाद उत्तर प्रदेश की रहने वाली हूँ मेरी बेटी दिव्यांशी 12 वर्षकी है उसे स्टीमा नामक रोग से पहले 12 साल से पीड़ित हैं इस विमारी की वजह से मेरी बच्ची के बहो सरी तकलीफ बहो रही है मैं संस्था से निवेदन करना चाहती हूँ वह मेरी आर्थी सहायता प्रदान करें।

प्रार्थी मीता पाठक  
ग्राम बलरामपुर  
कैलाबाद हैदरगंज  
उत्तर प्रदेश

8808742405



Fingerprints.



अखिल भारतीय आयुर्विज्ञान संस्थान, नई दिल्ली  
ALL INDIA INSTITUTE OF MEDICAL SCIENCES, NEW DELHI  
DEPARTMENT OF PATHOLOGY

Patient Name	: DIVYANSHI DIVYANSHI	UHID NO.	: 106614011
Accession No	: S2428045	F/H Name	: D/O SANTOSH KUMAR PATHAK
Age/Sex	: 11Y /Female	Additional ID	: NA
Clinic/Dept	: Paediatric Surgery	Unit	: N/A
Consultant Incharge	: Dr. Sachin A Borkar	Request Date/Time	: 19-06-2024 /17:05:49
		Receiving Date/Time	: 20-06-2024 /14:08:21

HISTOPATHOLOGY REPORT

GROSS EXAMINATION:

Accession No. : S2428045A

Specimen labelled as "seromuscular biopsy from colon above peritoneal reflection" comprises of single soft tissue piece measuring 0.4 × 0.3 × 0.3 cm.

MICROSCOPIC EXAMINATION:

Sections examined show colonic mucosa, submucosa and a part of muscle layer. Submucosa shows presence of few nerve fascicles, one of which shows ganglion cells.

Rest of the nerve fascicle in the submucosa and a part of muscle layer does not show any ganglion cells.

Overall features are not suggestive of aganglionosis.

However, possibility of hypoganglionosis is suggested.

DIAGNOSIS:

S2428045A

Colon biopsy

• Descriptive, see above

End Report

Reporting Resident: Dr. Sagir Akhtar

Reporting Faculty: Prof. Prasenjit Das

Reporting Date/Time: 27-06-2024 17:15

Disclaimer :

1. This report is electronically generated and does not require a signature or stamp to be considered valid.
2. The pathology diagnosis is to be interpreted by the treating physician in conjunction with clinical features, imaging, and other investigations.

child (11/1/E)  
 HD SIP @ Transverse  
 + SM Colostomy  
 ↓ possibility of  
 hypogastric

अ० भा० आ० सं० अस्पताल / A.I.I.M.S. HOSPITAL  
 बहिरंग रोगी विभाग / Out Patient Department



अस्पताल के अन्दर धूम्रपान मना है। / SMOKING IS PROHIBITED IN HOSPITAL PREMISES  
 DR. SACHIT ANAND  
 J-112, NEW DELHI  
 OPD  
 Unit \_\_\_\_\_  
 पंजीकृत सं० / O.P.D. Regn. No. \_\_\_\_\_

OPR-6  
 1066/4011

नाम / Name	पिता/पुत्र/पत्नी/पुत्री F/S/W/D of	लिंग Sex	आयु Age	पता / Address
Divyanshi	Santosh	♂	12y	

निदान / Diagnosis

दिनांक / Date  
 21/4/25  
 2  
 26/4

उपचार / Treatment  
 HD SIP (RTC)  
 16/6/24

Appointment on 11/8/25  
 Dept./Clinic

h/o constipation  
 ↓  
 Distal loop = GC - no  
 (alilan) UINB +  
 Colon = dilated at RLS zone.

↓  
 14/6/24 = RTC (SN)

↓  
 h/e = (Sahabouh)  
 abdominal soft = not suggestive of aganglionosis -  
 but possibly of hypoganglionosis -

Non distended wall in stomach  
 no abd distension.

↓  
 O/E = stomach fully, no prolapse.

↓  
 looks like  
 T2




CLEAN AND GREEN AIIMS / एम्स का यही संकल्प, स्वच्छता से काया कल्प  
 अंगदान-जीवन का बहुमूल्य उपहार / ORGAN DONATION - A GIFT OF LIFE  
 O.R.B.O., AIIMS, 26588360, 26593444, www.orbo.org Helpline - 1060 (24 hrs service)



17/2/25

w/r  
(19)



27 kg

F/U child (11y/F)

HD s/p (R) Transverse colostomy

+ sm Biopsy on

19/6/24

↓ possibility of hypoganglionosis

Appointments for  
Dent/Clinic

8/1/24. Rectal Biopsy → absent ganglion cells

hypertrophied nerve bundles.

no worms now.

Stool culture. @ AIIMS, ND.

26/12/24.

O/E: Stoma functional.

No salmonella/shigella/vibrio grown on culture.

D/w Dr Sachit Anand MD

Adv.

- Tab albendazole 400 mg HS

↓  
400 mg HS after 1 month.

- Review on 24/4/2025.

Observed  
Paeds Sr. Sr.

10 मां आं सं० अस्प  
बहिरंग रोगी विभाग / C  
Child Surgical S. R.  
Child Ward, 34/35-37  
DR. SA  
Unit/Dept.  
F/S/W/D



अ. भा. आ. सं. अस्पताल / **A.I.I.M.S. HOSPITAL**  
 बहिरंग रोगी विभाग / **Out Patient Department**



शुभ्रपान मना हे। / **SMOKING IS PROHIBITED IN HOSPITAL PREMISES**

Children Surgical C. 11

**DR. SACHITANAND**  
 AIIMS, NEW DELHI

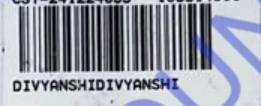OPR-6

106614011

एकक / Unit  
 विभाग / Dept

रो.वि. पंजीकृत सं. / O.P.D. Regn. No.

CST-241224033 106614011



DIVYANSHIDIVYANSHI

नाम / Name	पिता / पुत्र / पत्नी / पुत्री F/S/W/D of	लिंग Sex	आयु Age
Divyanshi	Dr. Santosh	M	1 1/2 y

MSL-241224008 106614011



DIVYANSHIDIVYANSHI

निदान / Diagnosis

HD S/P R/Tc clg

दिनांक / Date  
 12/23/24

उपचार / Treatment  
 - do hearns in

- e pain abdomen

- on R/Tc - stone functions

Adv. - T. Albedazole 200mg one

dose stat

↓

T. Albedazole 200mg one

dose after 14 days

⇒ stool one / clt / anal cyst / parasite

- Paeds review

- R/O 24/3/25 for date for

- ~~Stomach~~

- Stomach clinic review

Appointment on  
 for  
 Dept./Clinic



CLEAN AND GREEN AIIMS / एम्स का यही संकल्प, स्वच्छता से काया कल्प  
 अंगदान - जीवन का बहुमूल्य उपहार / ORGAN DONATION - A GIFT OF LIFE  
 O.R.B.O., AIIMS, 26588360, 26593444, www.orbo.org Helpline - 1060 (24 hrs service)

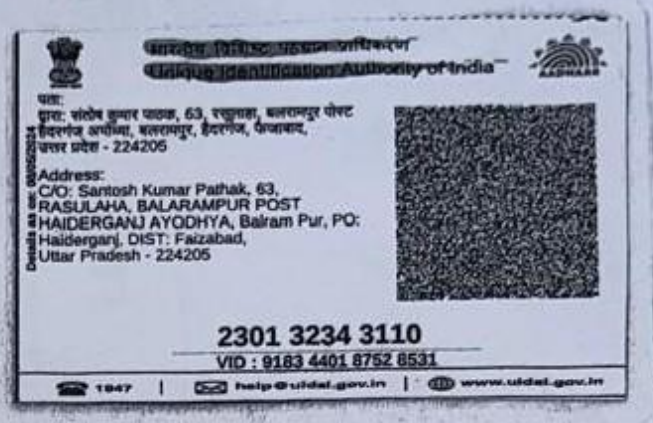
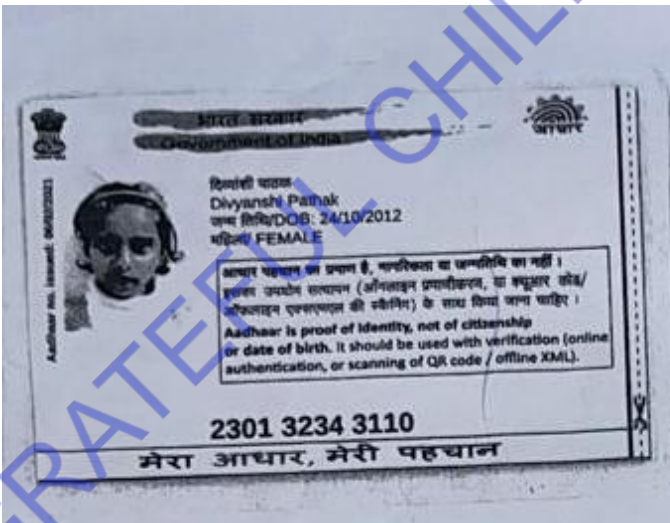
meraaspatal.nhp.gov.in

Sachin  
 वरिष्ठ रेजिडेन्ट / Senior Resident  
 विभाग / Dept. of Pediatric Surgery  
 अ. भा. आ. सं. / A.I.I.M.S., New Delhi-29







Grateful Child Welfare  
Foundation

+91 99581 14443



9958114443@okbizaxis



BHIM L1PI

**Beneficiary Name:** Grateful Child Welfare Foundation

**A/C Number:** 023788700000384

**Bank Name:** YES Bank

**Branch:** Naraina, New Delhi

**IFSC Code:** YESB0000237