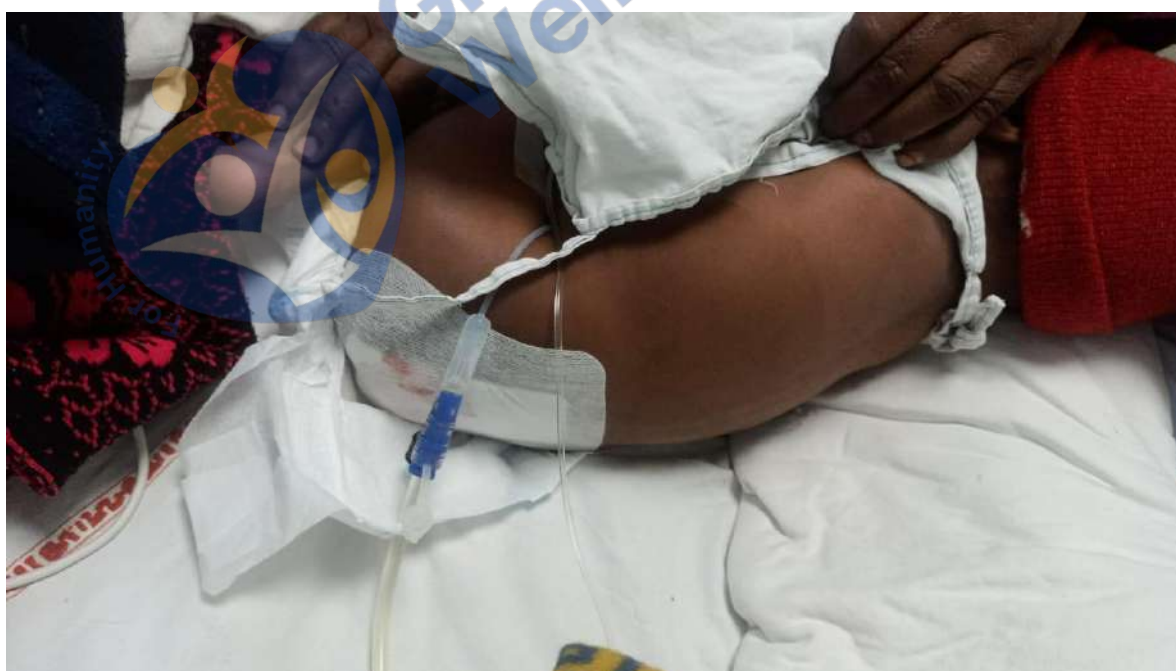
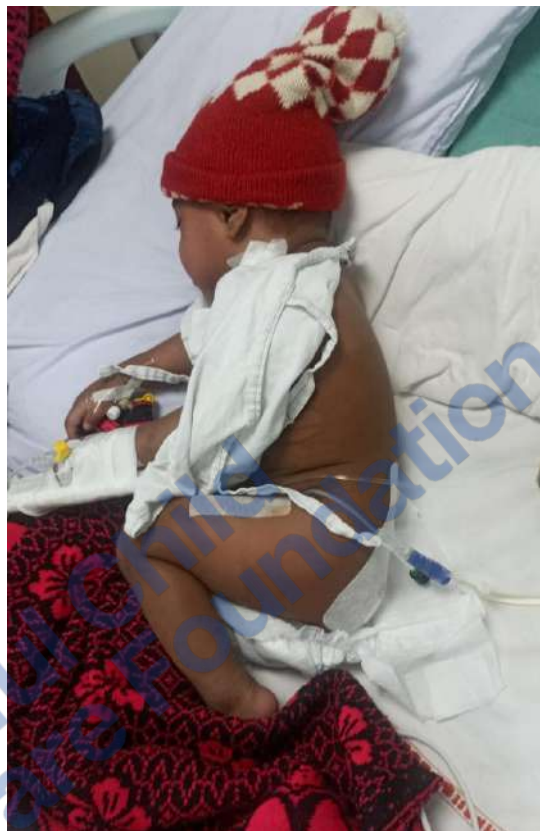
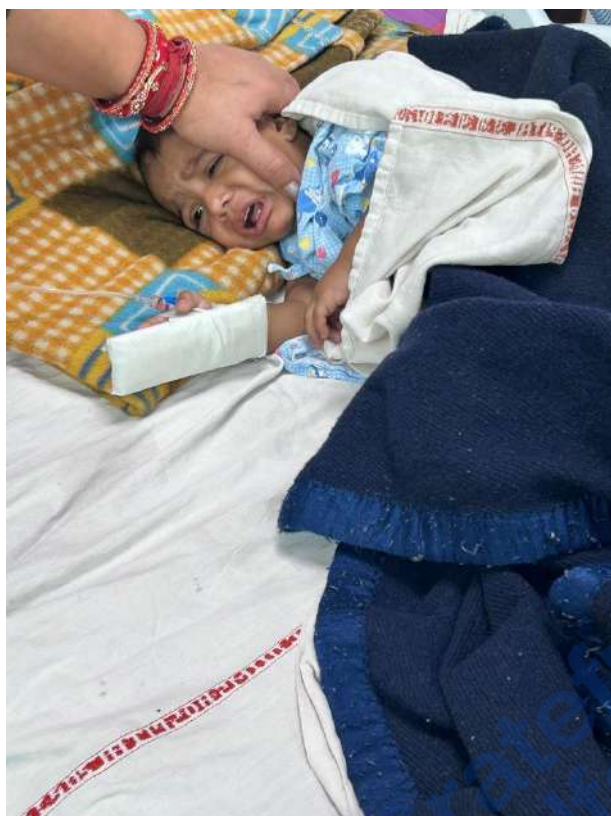Baby Ishika, a 1-year and 4-month-old girlchild is currently undergoing treatment for Sacrococcygeal Teratoma (Tumor) at AIIMS, New Delhi. The medical expenses, including surgeries and medications, have placed an immense burden on the family's limited resources where his father is a poor labourer working in Firozabad. We are reaching out to seek your assistance in alleviating the financial strain that the family is currently facing.



Ishika's medical documents are mentioned in this file, please go through them and come forward to donate for this life.

**अ० भा० आ० सं० अस्पताल / A.I.I.M.S. HOSPITAL**  
**बहिरंग रोगी विभाग / Out Patient Department**  
 अस्पताल में अंशक धूमपान करना है / SMOKING IS PROHIBITED IN HOSPITAL PREMISES

OPR-6

एकक/Unit: **बाल शल्यचिकित्सा**  
 विभाग/De: **Paediatric Surgery OPD**

UHD: 106973392  
 Dept No.: 20230220005269

डॉ. अशोक कुमार  
 14/11/2023  
 Queue: F33

रोगी का नाम: **ISHIKA ISHIKA**  
 DOB: **21/11/23**  
 1Y 6M 15D (संस्कृत)  
 Add: **NAGLA SURAJ, POST: HEMVATPURA TUNDLA, FARUKHABAD, UTTAR PRADESH - PIN: INDIA**  
 Web: **963403027 Follow Up Patient General 0**

रोगी का पता: **106973392**  
 14/11/2023  
**MGCT - SCT**

रिपोर्टिंग: 09:15:50

रिक्त/Date: **21** **6-8/11/23**

उपचार: **OPRC - 8/11/23**

उपचार: **CGCT abd + Pelvis - 31.10.23**  
 Tumor ⊕  
 No fat plane E rectum

उपचार: **CGCT abd + chest + Pelvis - 3/11/23**  
 Hypodense lesion in presacral region  
 Displacing rectum & bladder.  
 No intraspinal extension.  
 chest ⊕

Plan - Resection.  
 H/o URI ⊕. No fever ⊕  
 Swelling had after chemo.  
 No H/o Pain abd / abd distention.

2 Courses of PEBs -  
 15/9/23 to 7/10/23.

S-APP-30 8/23 - 46, 049.  
 25/10/23 - 34.5 ng/ml

cd/dw Dr. Vishesh Jais  
 Adm. sy. Acetaminophen (250mg/5ml)  
 2.5 ml / po / TDS  
 x 7 days

Steam inhalation  
 Ha. Wcra - 40 ports for 5x  
 Once URI substitute.

ANMS FREE GENERIC PHARMACY  
 MEDICINE PROVIDED  
 14/11/23

CLEAN AND GREEN ANMS / एम्स का यही संकल्प, स्वच्छता से काया कल्प  
 अंगदान जीवन का बहुमूल्य उपहार / ORGAN DONATION - A GIFT OF LIFE  
 O.R.B.O., ANMS, 26588360, 593444, www.aibo.org Helpline: 3060 (24 hrs service)

श्री अशोक कुमार, बाल शल्य विभाग / Dept. of Paediatric Surgery, A.I.I.M.S., New Delhi-110029

मेरा अस्पताल  
 My Hospital  
 meraaspatal.nhp.gov.in

आखिल भारतीय आयुर्विज्ञान संस्थान / ALL INDIA INSTITUTE OF MEDICAL SCIENCES  
 अंसारी नगर, नई दिल्ली-110029 / ANSARI NAGAR, NEW DELHI - 110029  
 फॉर्मेट (सती एवं पुरुषी रिपोर्ट) / FACSIMILE (ADMISSION AND DISCHARGE RECORD)

NON-MLC

कें.पं.सं. / C.R. No. 11-530101-23

वार्ड/बिस्तर सं. / WARD / BED NO. NICH618/18

दिनांक / DATE 24/11/2023

नाम / NAME: MISS ISHIKA ISHIKA

पिता/पति का नाम / FATHER / HUSBAND NAME: D/O JAY KISHAN

माता का नाम / MOTHER NAME: Other

व्यवसाय / OCCUPATION: Other

स्थानीय पता अथवा नजदीकी रिश्तेदार एवं उसका पता / LOCAL ADDRESS OR NEXT OF KIN WITH ADDRESS:

स्थायी पता / PERMANENT ADDRESS: NAGLA SURAJ, POST-HIMMATPUR TUNDLA, FIROZABAD

राज्य / STATE: null INDIA

विभाग का विवरण / DEPARTMENT DETAILS

विभाग / DEPARTMENT: PAED SURGERY

यूनिट / UNIT: Dr. VISHESH JAIN

यूनिट अध्यक्ष / UNIT HEAD: Dr. VISHESH JAIN

परामर्शदाता / CONSULTANT:

को.पी.टी./अपात सं./OPD/CASUALTY NO.:

छुट्टी पर तैनात कें.प्र.का. स्टाफ का नाम NAME OF CAO STAFF ON DUTY: HHD No. 106973392

मिति / DATE: 24/11/2023

मिति / DATE: 06:31

छुट्टी की तिथि / DATE OF DISCHARGE:

छुट्टी पर तैनात कें.प्र.का. स्टाफ के हस्ताक्षर / SIGN. OF CAO STAFF ON DUTY:

निदान एवं अन्य / DIAGNOSIS & OTHERS

अस्थायी निदान / PROVISIONAL DIAGNOSIS:

टिप्पणी / REMARKS: Sacro coccygeal Teratoma - Altmann Type 3

अंतिम निदान / FINAL DIAGNOSIS: Sacro coccygeal Teratoma - Altmann Type 3

द्वितीयक निदान एवं जटिलताएं / SECONDARY DIAGNOSIS & COMPLICATIONS:

मृत्यु का कारण / CAUSE OF DEATH:

परिणाम: उपचार से ठीक हुए/स्वास्थ्य में सुधार/कोई परिवर्तन नहीं/अनुरोध करने पर छुट्टी की गई/लामा/फरार/गंभीर/मृत्यु होना। / RESULT: CURED/IMPROVED/UNCHANGED/DISCHARGED ON REQUEST/LAMA/ABSCONDED/WORSE/EXPIRED

वरिष्ठ रेजीडेंट का नाम एवं हस्ताक्षर / NAME & SIGN. OF SR. RESIDENT:

परामर्शदाता के हस्ताक्षर / SIGN. OF CONSULTANT:

एम.आर.-3 जनरल हिस्ट्री  
M.R.- 3 General History

अखिल भारतीय आयुर्विज्ञान संस्थान, नई दिल्ली-110029  
ALL INDIA INSTITUTE OF MEDICAL SCIENCES, NEW DELHI-110029

नाम Name - Ishika  
उम्र Age 1 1/2 y/F  
सर्विस Service  
दिनांक Date 24/11/23  
यू.एच.आई.डी. नं. UHID No. ID 6978392  
प्रोफेसर इंचार्ज Professor I/C - Dr V Jain (MCH/GB-18)  
Notes written by Dr C Goswami

CLINICAL NOTES (Initial assessment)

Name :- Ishika

Informant :- Aunt

Age :- 1 1/2 years / Female

Reliability :- Fair.

Add :- Tundla, Firozabad

Phn :- 9634033827

Chief complaint :- Constipation - 4 months  
Swelling in lower back & gluteal region - 4 months

History of present illness :- Child was apparently well 4 months back from when she started to have constipation. Initially to start with, she used to pass hard stool regularly but frequency of passage decreased over few days and

PHYSICAL EXAMINATION

Temp.	Pulse	Resp.	B.P.	Weight
-------	-------	-------	------	--------

associated = hard stool. Along with this there is also w/o swelling over lower back. Swelling was insidious in onset, ~~slowly~~ rapidly progressive involved lower back initially with gluteal region later, swelling was initially small but rapidly increased to large size. There is no associated pain, skin discoloration, bleeding, discharge, ulcer over swelling.

- No w/o pain abdomen, abdominal fullness, vomiting elsewhere, urinary complaints like dribbling, straining, retention.

No w/o fever, rash, joint swelling, seizure.

past medical h/o :- None significant

past surgical h/o :- None



एम.आर.-3 जनरल हिस्टरी  
M.R.- 3 General History

अखिल भारतीय आयुर्विज्ञान संस्थान, नई दिल्ली-110029  
ALL INDIA INSTITUTE OF MEDICAL SCIENCES, NEW DELHI-110029

नाम  
Name Ishika

उम्र  
Age

सर्विस  
Service

दिनांक  
Date

यू.एच.आई.डी. नं.  
UHID No.

प्रोफेसर इंचार्ज  
Professor I/C

106973392

Notes written by .....

(28/11/23)

CLINICAL NOTES

6.8kg

Preop orders ~~following~~ for resection of  
SCT

- NPO from 2AM
- IVF N/3Ds + KCl (1:100) @ 28.3ml/hr
- Inj. Augmentin 200mg } AST & send vid
- Inj. Gentamicin 15mg } to OT
- IIV consent
- Stoma consent
- follow PAE orders
- Glycerine syringing (10+10ml) stat & HS
- Shift pt to OT on call.
- Steam inhalation stat before shift to OT.

Goswami

ALL INDIA INSTITUTE OF MEDICAL SCIENCES

नाम Name	उम्र Age	सर्विस Service	दिनांक Date	यू.एच.आई.डी. नं. UHID No.
प्रोफेसर इंवारज Professor I/C				

Notes written by .....


**CLINICAL NOTES**

28/11/2023. PAE  
 14 months / F / 6.8 kg      Dx: Sacrococcygeal teratoma

- Preterm LGS (7 months) - CIAS, LRH - NICU stay.
- delayed milestones - not holding 9 months.
- Last episode of URI - 9 days back.
- H/o consolidation & swelling over lower back - 4 months.  
 Received two cycles of chemotherapy at JIPMER & AIIMS:
  - VP-16 - Atoponide.
  - Cisplatin.
  - Bleomycin.
- No other comorbidities.

PE: PR: 110 bpm. Chest: Clear. WNL. Abdomen - Pediatric obesity - feces - normal. Abdominal check-up + swelling (H)

Grateful Child Welfare Foundation



**PROGRESS NOTES**

Date	Remarks	Investigation Advised	Treatment Advised
27/11/23	<p>wt. 6.8kg</p> <p>Dr. Krishant et al</p> <p>↓ GA + caudal</p> <p>IVF =</p> <p>Blood loss = 30ml</p> <p>Duration = 3½ hrs</p> <p>8 Fr Foley as pvc</p>	<p>Postop orders following ↓ GA + caudal</p>	<p>Excision of SCT caudal (GD/CG/PA) VJ</p>
		<ul style="list-style-type: none"> <li>- NPO <del>HH</del></li> <li>- IVF N<sub>2</sub>O<sub>5</sub> @ 28-3 25ml/hr</li> <li>- Inj. Augmentin 200mg iv q 8hly</li> <li>- Inj. Gentamicin 15mg iv q 8hly</li> <li>- Inj. PCM 100mg iv q 6hly</li> <li>- Monitor TPR/I/O.</li> <li>- Catheter care.</li> <li>- Inform JR/SR 800.</li> </ul>	


Chavan

**अखिल भारतीय आर्युर्विज्ञान संस्थान**  
**ALL INDIA INSTITUTE OF MEDICAL SCIENCES**

पंजीकृत: 1956  
 पंजीकृत: 1956  
 पंजीकृत: 1956

पंजीकृत: 1956  
 पंजीकृत: 1956  
 पंजीकृत: 1956

पंजीकृत: 1956  
 पंजीकृत: 1956  
 पंजीकृत: 1956





## Information for Sending Your Donations:

Grateful Child Welfare  
Foundation

+91 99581 14443



9958114443@okbizaxis



**Beneficiary Name:** Grateful Child Welfare Foundation

**A/C Number:** 023788700000384

**Bank Name:** YES Bank

**Branch:** Naraina, New Delhi

**IFSC Code:** YESB0000237

**Address:** E/34, Ground Floor, Naraina Vihar, New Delhi, Delhi 110028

For any information on this case, please connect with us.